Brief Report

White Matter Abnormalities in First-Episode Schizophrenia or Schizoaffective Disorder: A Diffusion Tensor Imaging Study

Philip R. Szeszko, Ph.D.
Babak A. Ardekani, Ph.D.
Manzar Ashtari, Ph.D.
Sanjiv Kumra, M.D.
Delbert G. Robinson, M.D.
Serge Sevy, M.D.
Handan Gunduz-Bruce, M.D.
Anil K. Malhotra, M.D.
John M. Kane, M.D.
Robert M. Bilder, Ph.D.
Kelvin O. Lim, M.D.

Objective: The goal of this study was to investigate brain white matter abnormalities by using diffusion tensor imaging in patients with schizophrenia or schizoaffective disorder close to illness onset.

Method: Ten patients experiencing a first episode of schizophrenia or schizoaffective disorder and 13 healthy volunteers received diffusion tensor imaging and structural magnetic resonance imaging examinations. Voxel-wise analysis was used to compare fractional anisotropy maps in the white matter of the two groups following intersubject registration to Talairach space.

Results: Compared with healthy volunteers, patients demonstrated lower fractional anisotropy in the left internal capsule and left-hemisphere white matter of the middle frontal gyrus and posterior superior temporal gyrus. There were no areas of significantly higher fractional anisotropy in patients compared with healthy volunteers.

Conclusions: These findings suggest that white matter pathology is present early in the course of schizophrenia and may be less pronounced than has been found in previous diffusion tensor imaging studies of patients with chronic illness. Further, these data are consistent with hypotheses regarding frontotemporal dysfunction and the failure of left-hemisphere lateralization in the pathophysiology of schizophrenia.

(Am J Psychiatry 2005; 162:602–605)

Abnormalities in brain white matter have been hypothesized to play a key role in the pathophysiology of schizophrenia (1). Postmortem studies have identified abnormalities in the myelin sheath (2), oligodendroglia (3), and interstitial neurons (4) in patients compared with healthy volunteers. If the pathophysiology of schizophrenia reflects a disturbance in the white matter, then such abnormalities might be observed by using diffusion tensor imaging. Several previous studies reported lower anisotropic diffusion (5–12) and a lack of normal asymmetry in this diffusion (10) among patients with schizophrenia compared with healthy volunteers, although some studies (13, 14) did not identify differences between subjects with and without schizophrenia in white matter integrity.

Previous diffusion tensor imaging studies may be limited by the use of patients who were chronically ill. Examination of brain white matter closer to onset of illness in schizophrenia may be important, especially given recent evidence for a progressive reduction in white matter volume over the course of the illness (15). In this study we report a voxel-wise analysis of diffusion tensor imaging data in patients experiencing a first episode of schizophrenia or schizoaffective disorder studied early in the course of their illness. We hypothesized that these patients would demonstrate lower fractional anisotropy compared with healthy volunteers and that these effects would be greatest in the frontal and temporal lobes, consistent with hypotheses regarding frontolimbic dysfunction (16–18).

Method

The 10 patients included in this study (six men, four women, mean age=26.9 years, SD=4.6) were recruited from The Zucker Hillside Hospital in Glen Oaks, N.Y. Patients were experiencing a first episode of illness and had been taking antipsychotic medications for a median of 15 days. Four patients were antipsychotic-drug-naive at the time of the scan. Two patients were Caucasian, six were African American, and two were classified as "other." Diagnoses were based on the patient edition of the Structured Clinical Interview for DSM-IV Axis I Disorders (SCID) (19) and included schizophrenia (N=5) and schizoaffective disorder (N=5). Thirteen healthy volunteers (seven men, six women, mean age= 28.9, SD=6.0) also participated in this study; these subjects had no history of psychiatric illness, determined by using the nonpatient edition of the SCID (20). Seven healthy volunteers were Caucasian, two were African American, two were Hispanic, and two were classified as "other."

Exclusion criteria for all individuals included serious neurological or endocrine disorder, any medical condition or treatment known to affect the brain, or mental retardation defined according to DSM-IV criteria. Eight of the patients and 10 of the volunteers were dextral; two of the patients and three of the volunteers were nondextral. All procedures were approved by the local institutional review board, and written informed consent was obtained from all study participants.

Magnetic resonance imaging examinations were conducted on a 1.5-T system (GE Medical Systems, Milwaukee). Seven diffusion tensor imaging volumes were obtained for each subject, includ-

FIGURE 1. Regions in Which Fractional Anisotropy Was Significantly Lower in 10 Patients With Schizophrenia or Schizoaffective Disorder Compared With 13 Healthy Volunteers[a]

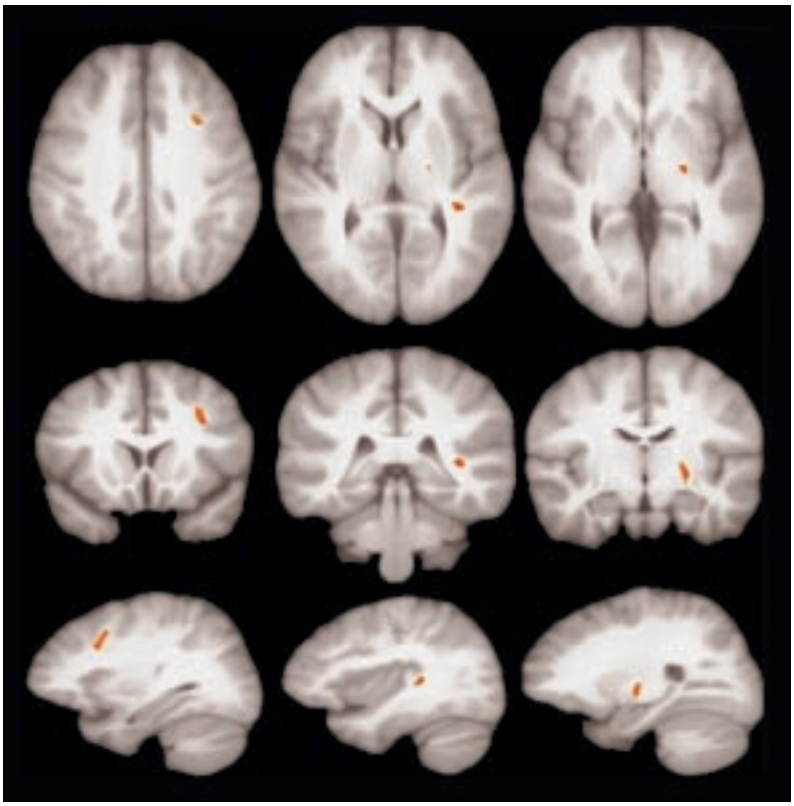

[a] The regions were the white matter in the middle frontal gyrus (column 1) (t=5.27, df=20, p<0.001, cluster size=225), in the posterior superior temporal gyrus (column 2) (t=5.08, df=20, p<0.001, cluster size=106), and in the internal capsule extending into the globus pallidus (column 3) (t=4.76, df=20, p<0.001, cluster size=129).

ing six volumes with diffusion gradients applied along six nonparallel directions (b=800 seconds/mm^2 and number of excitations=4) and one volume without diffusion weighting (b=0, number of excitations=2). Each volume consisted of 18 contiguous axial slices (slice thickness=5 mm) acquired parallel to the anterior-posterior commissure by using a pulsed-gradient, spin-echo, single-shot echo planar imaging method (TR=8 seconds, TE=101 msec; 128×128 matrix, field of view=24 cm). This analysis used slices that began 5 mm below the anterior commissure and proceeded superiorly because this part of the brain encompassed the largest extent of cerebral white matter.

One hundred twenty-four contiguous coronal images (slice thickness=1.5 mm) were acquired through the whole head by using a three-dimensional fast spoiled-gradient recall acquisition sequence with IR-Prep (TR=12.7 or 14.7 seconds, TE=4.5 or 5.5 msec, field of view=22 cm) in a 256×256 matrix. In addition, an oblique axial dual double-echo spin-echo scan (TR=5 seconds, TE=22/90 msec, 256×256 matrix, field of view=240 mm, 26 slices, 5-mm slice thickness, 0-mm gap) was acquired at the same slice positions as the diffusion tensor images, providing a pair of T_2- and proton density-weighted volumes. The T_2/proton density volumes were used to correct image distortion on the diffusion tensor images and for image segmentation.

Fractional anisotropy maps (21, 22) for each subject were computed and registered to Talairach space (23) by applying three image registration steps. First, all spoiled-gradient recall acquisition volumes were matched to a target volume in Talairach space by using an in-house nonlinear registration software program (24, 25). This algorithm is based on previously published methods (26–28) with additional features for computational efficiency (24, 25). Second, the T_2- and proton density-weighted volumes were registered to the spoiled-gradient recall acquisition volume within each subject (29). Third, the b=0 diffusion tensor imaging volume was registered to the T_2 volume to correct for spatial distortion in fractional anisotropy maps (24, 25). The transformations from these three registration steps were combined numerically and applied to the fractional anisotropy maps by using a single interpolation operation.

A white matter mask was created for each subject with FSL software (30) by segmenting the brain on the basis of the T_2, proton density, and spoiled-gradient recall acquisition volumes. The white matter mask was also transformed to Talairach space. The transformed white matter masks were averaged and thresholded at 40% to obtain a white matter mask for each group. Both the registered fractional anisotropy and white matter images were smoothed with a three-dimensional isotropic Gaussian kernel with a sigma of 3 mm.

Group differences in demographic variables were examined by using independent-group t tests or chi-square tests. To control for potential partial volume effects in our analysis, fractional anisotropy values for each voxel were adjusted for white matter intensity through linear regression. Two-sample t tests comparing patients and healthy subjects were performed at each voxel on the corrected fractional anisotropy values. Voxels that had a t value greater than 3.85 (p<0.001, two-tailed) and were part of a spatially contiguous cluster size of 100 voxels or greater were considered to be significantly different between groups.

Results

Patients and comparison subjects did not differ significantly in distribution of age, sex, parental social class, race, or handedness ($p>0.05$). Significantly lower fractional anisotropy in patients compared with healthy volunteers was observed in three regions of the left hemisphere (Figure 1), including the white matter in the middle frontal gyrus ($t=5.27$, $df=20$, $p<0.001$, cluster size=225), in the posterior superior temporal gyrus ($t=5.08$, $df=20$, $p<0.001$, cluster size=106), and in the internal capsule extending into the globus pallidus ($t=4.76$, $df=20$, $p<0.001$, cluster size=129). Talairach coordinates representing the centroid (x=right, y=anterior, and z=superior) in the middle frontal gyrus were x=–30, y=15, z=35; in the temporal lobe they were x=–36, y=–32, z=8; in the internal capsule/globus pallidus they were x=–22, y=–12, z=2. Similar findings were obtained when analyses were restricted to the subgroup of patients who had never taken antipsychotic drugs. There were no areas of significantly higher fractional anisotropy in patients compared with healthy volunteers.

Discussion

Our findings suggest that patients experiencing a first episode of schizophrenia or schizoaffective disorder exhibit lower anisotropic diffusion in brain white matter. Lower anisotropic diffusion could be associated with either micro- or macrostructural alterations involving the myelin sheath and/or directional coherence of fiber tracts. Abnormalities appeared less pronounced in this group of patients experiencing their first episode of schizophrenia or schizoaffective disorder than has been found in studies of patients with chronic illness (8, 9). In that regard, our findings converge with those of Bagary et al. (31), who reported relatively circumscribed white matter abnormalities inferred from magnetization transfer imaging in first-episode patients compared with healthy volunteers.

Previous diffusion tensor imaging studies that quantified anisotropic diffusion in patients reported abnormalities in the prefrontal white matter (11, 12) and corpus callosum (5, 6) as well as more widespread abnormalities in the brain (8, 9). Other diffusion tensor imaging studies specifically investigating white matter connectivity reported abnormalities in the uncinate fasciculus in patients compared with healthy volunteers (7, 10). Some studies, however, did not identify group differences in anisotropy (13, 14). Differences in illness duration, image processing, and analysis, including the use of region-of-interest versus voxel-wise approaches, could account for discrepant findings.

Decreased fractional anisotropy was observed among patients in the left middle frontal gyrus white matter, which is consistent with postmortem findings (4, 32). Moreover, this part of the middle frontal gyrus corresponds anatomically to the dorsolateral prefrontal cortex, which has also been widely implicated in the pathophysiology of schizophrenia (33). We also observed lower fractional anisotropy among patients in the white matter in the vicinity of the left planum temporale and Heschl gyrus. Our findings thus converge with those of previous volumetric magnetic resonance imaging studies implicating less left-hemisphere gray matter in these regions among patients experiencing their first illness episode (34) compared with healthy volunteers.

There are several limitations to this study, including the small number of subjects and risk of a type I error. To limit the possibility of a type I error, however, we investigated fractional anisotropy only in the brain white matter; therefore, it appears noteworthy that we did not observe any areas of increased fractional anisotropy in patients, thus strengthening the specificity of the observed findings. A possible limitation of the segmentation is that it may have reduced contrast of the lentiform nucleus with the surrounding white matter, thus increasing the risk of tissue misclassification in the area of the globus pallidus.

In summary, we present evidence for white matter pathology as inferred from diffusion tensor imaging in patients with schizophrenia or schizoaffective disorder examined early in the course of illness. Future studies could use diffusion tensor imaging to examine whether such abnormalities are progressive as well as possible sex differences in white matter microstructure in schizophrenia (35).

Received Jan. 30, 2004; revision received May 25, 2004; accepted June 10, 2004. From the Department of Psychiatry Research, The Zucker Hillside Hospital, North Shore-Long Island Jewish Health System; and the Department of Radiology, North Shore-Long Island Jewish Health System, New Hyde Park, N.Y. Address correspondence and reprint requests to Dr. Szeszko, The Zucker Hillside Hospital, Department of Psychiatry Research, 75–59 263rd St., Glen Oaks, NY 11004; szeszko@lij.edu (e-mail).

Supported in part by grants from the National Alliance for Research on Schizophrenia and Depression (Drs. Szeszko and Lim), grant P41 RR-009784 from the Center for Advanced MR Technology at Stanford University, grant RG-00-0350 from the Whitaker Foundation (Dr. Ardekani), and NIMH grants MH-01990 (Dr. Szeszko), MH-60374 (Dr. Bilder), MH-60575 (Dr. Kane), and MH-60004 (Dr. Robinson).

The authors thank Richard Mudge for assistance in data collection and management.

References

1. Davis KL, Stewart DG, Friedman JI, Buchsbaum M, Harvey PD, Hof PR, Buxbaum J, Haroutunian V: White matter changes in schizophrenia: evidence for myelin-related dysfunction. Arch Gen Psychiatry 2003; 60:443–456
2. Uranova N, Orlovskaya D, Vikhreva O, Zimina I, Kolomeets N, Vostrikov V, Rachmanova V: Electron microscopy of oligodendroglia in severe mental illness. Brain Res Bull 2001; 55:597–610
3. Hof PR, Haroutunian V, Copland C, Davis KL, Buxbaum JD: Molecular and cellular evidence for an oligodendrocyte abnormality in schizophrenia. Neurochem Res 2002; 27:1193–1200
4. Akbarian S, Kim JJ, Potkin SG, Hetrick WP, Bunney WE Jr, Jones EG: Maldistribution of interstitial neurons in prefrontal white matter of the brains of schizophrenic patients. Arch Gen Psychiatry 1996; 53:425–436

5. Foong J, Maier M, Clark CA, Barker GJ, Miller DH, Ron MA: Neuropathological abnormalities of the corpus callosum in schizophrenia: a diffusion tensor imaging study. J Neurol Neurosurg Psychiatry 2000; 68:242–244
6. Agartz I, Andersson JL, Skare S: Abnormal brain white matter in schizophrenia: a diffusion tensor imaging study. Neuroreport 2001; 12:2251–2254
7. Burns J, Job D, Bastin ME, Whalley H, Macgillivray T, Johnstone EC, Lawrie SM: Structural disconnectivity in schizophrenia: a diffusion tensor magnetic resonance imaging study. Br J Psychiatry 2003; 182:439–443
8. Lim KO, Hedehus M, Moseley M, de Crespigny A, Sullivan EV, Pfefferbaum A: Compromised white matter tract integrity in schizophrenia inferred from diffusion tensor imaging. Arch Gen Psychiatry 1999; 56:367–374
9. Ardekani BA, Nierenberg J, Hoptman MJ, Javitt DC, Lim KO: MRI study of white matter diffusion anisotropy in schizophrenia. Neuroreport 2003; 14:2025–2029
10. Kubicki M, Westin C-F, Maier SE, Frumin M, Nestor PG, Salisbury DF, Kikinis R, Jolesz FA, McCarley RW, Shenton ME: Uncinate fasciculus findings in schizophrenia: a magnetic resonance diffusion tensor imaging study. Am J Psychiatry 2002; 159:813–820
11. Buchsbaum MS, Tang CY, Peled S, Gudbjartsson H, Lu D, Hazlett EA, Downhill J, Haznedar M, Fallon JH, Atlas SW: MRI white matter diffusion anisotropy and PET metabolic rate in schizophrenia. Neuroreport 1998; 9:425–430
12. Kumra S, Ashtari M, McMeniman M, Vogel J, Augustin R, Becker DE, Nakayama E, Gyato K, Kane JM, Lim K, Szeszko P: Reduced frontal white matter integrity in early-onset schizophrenia: a preliminary study. Biol Psychiatry 2004; 55:1138–1145
13. Foong J, Symms MR, Barker GJ, Maier M, Miller DH, Ron MA: Investigating regional white matter in schizophrenia using diffusion tensor imaging. Neuroreport 2002; 13:333–336
14. Steel RM, Bastin ME, McConnell S, Marshall I, Cunningham-Owens DG, Lawrie SM, Johnstone EC, Best JJ: Diffusion tensor imaging (DTI) and proton magnetic resonance spectroscopy (1H MRS) in schizophrenic subjects and normal controls. Psychiatry Res 2001; 106:161–170
15. Ho BC, Andreasen NC, Nopoulos P, Arndt S, Magnotta V, Flaum M: Progressive structural brain abnormalities and their relationship to clinical outcome: a longitudinal magnetic resonance imaging study early in schizophrenia. Arch Gen Psychiatry 2003; 60:585–594
16. Bilder RM, Degreef G: Morphologic markers of neurodevelopmental paths to schizophrenia, in Developmental Neuropathology of Schizophrenia. Edited by Mednick SA, Cannon TD, Barr CE, LaFosse JM. New York, Plenum, 1991, pp 167–190
17. Szeszko PR, Goldberg E, Gunduz-Bruce H, Ashtari M, Robinson D, Malhotra AK, Lencz T, Bates J, Crandall DT, Kane JM, Bilder RM: Smaller anterior hippocampal formation volume in antipsychotic-naive patients with first-episode schizophrenia. Am J Psychiatry 2003; 160:2190–2197
18. Szeszko PR, Strous RD, Goldman RS, Ashtari M, Knuth KH, Lieberman JA, Bilder RM: Neuropsychological correlates of hippocampal volumes in patients experiencing a first episode of schizophrenia. Am J Psychiatry 2002; 159:217–226
19. First MB, Spitzer RL, Gibbon M, Williams JBW: Structured Clinical Interview for DSM-IV Axis I Disorders, Patient Edition (SCID-P), version 2. New York, New York State Psychiatric Institute, Biometrics Research, 1998
20. First MB, Spitzer RL, Gibbon M, Williams JBW: Structured Clinical Interview for DSM-IV-TR Axis I Disorders—Non-Patient Edition (SCID-I/NP). New York, New York State Psychiatric Institute, Biometrics Research, 2001
21. Basser PJ, Pierpaoli C: A simplified method to measure the diffusion tensor from seven MR images. Magn Reson Med 1998; 39:928–934
22. Basser PJ: Inferring microstructural features and the physiological state of tissues from diffusion-weighted images. NMR Biomed 1995; 8:333–344
23. Talairach J, Tournoux P: Co-Planar Stereotaxic Atlas of the Human Brain: Three-Dimensional Proportional System. New York, Thieme Medical, 1988
24. Ardekani BA, Bachman AH, Strother SC, Fujibayashi Y, Yonekura Y: Impact of inter-subject image registration on group analysis of fMRI data. Int Congr Ser 2004; 1265C:49–59
25. Ardekani BA, Guckemus S, Bachman A, Hoptman MJ, Wojtaszek M, Nierenberg J: Quantitative comparison of algorithms for inter-subject registration of 3D volumetric brain MRI scans. J Neurosci Meth 2004; 142:67–76
26. Kjems U, Strother SC, Anderson J, Law I, Hansen LK: Enhancing the multivariate signal of [15O] water PET studies with a new nonlinear neuroanatomical registration algorithm. IEEE Trans Med Imaging 1999; 18:306–319
27. Kosugi Y, Sase M, Kuwatani H, Kinoshita N, Momose T, Nishikawa J, Watanabe T: Neural network mapping for nonlinear stereotactic normalization of brain MR images. J Comput Assist Tomogr 1993; 17:455–460
28. Collins DL, Holmes CJ, Peters TM, Evans AC: Automatic 3-D model-based neuroanatomical segmentation. Hum Brain Mapp 1995; 3:190–208
29. Ardekani BA, Braun M, Hutton BF, Kanno I, Iida H: A fully automatic multimodality image registration algorithm. J Comput Assist Tomogr 1995; 19:615–623
30. Oxford Centre for Functional Magnetic Resonance Imaging of the Brain: FSL-BET Version 1.2. Oxford, UK, Oxford University, 2000
31. Bagary MS, Symms MR, Barker GJ, Mutsatsa SH, Joyce EM, Ron MA: Gray and white matter brain abnormalities in first-episode schizophrenia inferred from magnetization transfer imaging. Arch Gen Psychiatry 2003; 60:779–788
32. Kirkpatrick B, Messias NC, Conley RR, Roberts RC: Interstitial cells of the white matter in the dorsolateral prefrontal cortex in deficit and nondeficit schizophrenia. J Nerv Ment Dis 2003; 191:563–567
33. Gluck MR, Thomas RG, Davis KL, Haroutunian V: Implications for altered glutamate and GABA metabolism in the dorsolateral prefrontal cortex of aged schizophrenic patients. Am J Psychiatry 2002; 159:1165–1173
34. Hirayasu Y, McCarley RW, Salisbury DF, Tanaka S, Kwon JS, Frumin M, Snyderman D, Yurgelun-Todd D, Kikinis R, Jolesz FA, Shenton ME: Planum temporale and Heschl gyrus volume reduction in schizophrenia: a magnetic resonance imaging study of first-episode patients. Arch Gen Psychiatry 2000; 57:692–699
35. Szeszko PR, Vogel J, Ashtari M, Malhotra AK, Bates J, Kane JM, Bilder RM, Frevert T, Lim K: Sex differences in frontal lobe white matter microstructure: a DTI study. Neuroreport 2003; 14:2469–2473